

## Editor's Choice – Multicentre Outcomes of Redo Fenestrated/Branched Endovascular Aneurysm Repair to Rescue Failed Fenestrated Endografts

Angelos Karelis <sup>a,\*</sup>, Stéphan Haulon <sup>b</sup>, Björn Sonesson <sup>a</sup>, Donald Adam <sup>c</sup>, Tilo Kölbel <sup>d</sup>, Gustavo Oderich <sup>e</sup>, Enrico Cieri <sup>f</sup>, Thomas Mesnard <sup>g</sup>, Eric Verhoeven <sup>h</sup>, Nuno Dias <sup>a</sup>, contributors

<sup>a</sup> Department of Thoracic Surgery and Vascular Diseases, Vascular Centre, Skåne University hospital, Malmö, Sweden

<sup>b</sup> Aortic Centre, Hôpital Marie Lannelongue, Groupe Hospitalier Paris Saint-Joseph, INSERM UMR\_S 999, Université Paris Saclay, Paris, France

<sup>c</sup> Complex Aortic Team, Birmingham Heartlands Hospital and Queen Elizabeth Hospital, University Hospitals Birmingham NHS Foundation Trust, Birmingham, UK

<sup>d</sup> Department of Vascular Medicine, German Aortic Centre, University Heart and Vascular Centre, Hamburg, Germany

<sup>e</sup> Health Science Centre, University of Texas, Houston, TX, USA

<sup>f</sup> Unit of Vascular & Endovascular Surgery, S. Maria della Misericordia Hospital, Perugia, Italy

<sup>g</sup> Aortic Centre, University of Lille, Inserm, CHU Lille, U1008, F-Lille, France

<sup>h</sup> Department of Vascular and Endovascular Surgery, General Hospital Nuremberg, Paracelsus Medical University, Nuremberg, Germany

### WHAT THIS PAPER ADDS

This study describes the promising feasibility and outcomes of proximal extension with new fenestrated/branched endovascular aneurysm repair (FEVAR/BEVAR) inside a previous failing FEVAR in many experienced aortic centres. Some of the technical challenges determined the technical success and further re-interventions were needed, but clinical success was high with no aneurysm related mortality. This establishes a baseline for comparison with other therapeutic options.

**Objective:** To report the outcomes of redo fenestrated and/or branched endovascular aortic repair (F/BEVAR in FEVAR) to rescue previous failed FEVAR.

**Methods:** Retrospective review of all consecutive patients undergoing F/BEVAR in FEVAR at eight aortic centres including pre-, intra-, and post-operative data according to a pre-established protocol. Follow up consisted of at least yearly computed tomography angiography. Values are presented as median and interquartile range, and survival as estimate  $\pm$  standard error in percentage.

**Results:** 18 male patients (76 years old; range 69 – 78 years) receiving FEVAR involving two (two or three) target vessels between 2006 and 2016 underwent F/BEVAR in FEVAR between 2012 and 2019 (aneurysm diameter of 63 mm; range 56 – 69 mm). Median interval between the procedures was 53 (29 – 103) months. The indication for F/BEVAR in FEVAR was type Ia endoleak in 16 cases (eight isolated and eight combined with graft migration), one graft migration without endoleak and one migration with significant proximal aortic expansion. F/BEVAR in FEVAR involved all patent renovisceral arteries and had an operating time of 260 (204 – 344) minutes. Technical success was achieved in 15 (83%) cases. There was a failure to bridge one renal artery, one renal capsular bleed with the subsequent need for renal artery embolisation within 24 hours and one persistent type Ib endoleak despite iliac extension. There was no peri- or in hospital death. Two patients developed spinal cord ischaemia, one transient paraparesis and one permanent paraplegia. The latter occurred in a non-staged procedure where spinal drainage was used. During a follow up of 27 (7 – 39) months, three (17%) patients underwent late re-interventions. Overall survival at 24 months was  $70 \pm 11\%$  with no aneurysm related death and a secondary clinical success at 24 months of  $84 \pm 11\%$ .

**Conclusion:** F/BEVAR in FEVAR is a technically challenging but feasible solution to rescue failed FEVAR. The outcomes are promising in many aortic centres but need to be confirmed by further studies with longer follow up.

**Keywords:** Complex endovascular aortic repair, Fenestrated branched abdominal aortic repair, Thoracoabdominal aneurysm

Article history: Received 10 January 2021, Accepted 30 June 2021, Available online 13 August 2021

© 2021 The Author(s). Published by Elsevier B.V. on behalf of European Society for Vascular Surgery. This is an open access article under the CC BY license (<http://creativecommons.org/licenses/by/4.0/>).

\* Corresponding author. Vascular centre, Department of Thoracic Surgery and Vascular Diseases, Skåne University Hospital, Ruth Lundskogs gata 10/1, 205 02 Malmö, Sweden.

E-mail address: [karelisangelos@gmail.com](mailto:karelisangelos@gmail.com) (Angelos Karelis).

1078-5884/© 2021 The Author(s). Published by Elsevier B.V. on behalf of European Society for Vascular Surgery. This is an open access article under the CC BY license (<http://creativecommons.org/licenses/by/4.0/>).

<https://doi.org/10.1016/j.ejvs.2021.06.038>

### INTRODUCTION

Over the past decade, fenestrated endovascular aneurysm repair (FEVAR) has become an established treatment with excellent short and midterm outcomes for complex aortic aneurysms. However, re-intervention after FEVAR may be

needed within three to five years, mostly related to the target vessels (5% – 15%) or endoleaks (4% – 10%).<sup>1–3</sup>

Type Ia endoleak after FEVAR constitutes a very challenging situation and pooled data reports a 2% occurrence.<sup>3</sup> No standard approach has been proposed to solve this complication. Conversion to open repair is much more challenging than after infrarenal EVAR and, to the best of the authors' knowledge, no series have been published. Recently, endovascular re-interventions have been recommended by the European guidelines as the first option for type Ia endoleaks after infrarenal EVAR.<sup>4</sup> However, the complexity of the endovascular redo procedure increases significantly when part of the renovisceral segment has been incorporated in the initial FEVAR hindering a proximal extension with simple thoracic endovascular aneurysm repair (TEVAR). Other endovascular solutions have been proposed including embolisation using glue or vascular plugs and proximal graft extensions with chimney grafts.<sup>5,6</sup> However, all of these techniques have drawbacks and limitations. Relining a failed FEVAR with a new fenestrated stent graft is theoretically an attractive alternative establishing a new proximal sealing zone while maintaining perfusion to the aortic side branches. In the literature, only a few case reports have described the use of F/BEVAR in FEVAR.<sup>7–10</sup>

The aim of this study was to report the midterm results of a series of consecutive F/BEVAR in FEVAR in eight experienced aortic centres.

## MATERIALS AND METHODS

### Patient population

Fifteen high volume aortic centres were invited to participate in this study. Ultimately, eight accepted and contributed patient data. All patients undergoing complex aortic aneurysm repair at eight experienced aortic centres were reviewed to identify and include those who underwent F/BEVAR in FEVAR due to previous FEVAR failure. No time restrictions were imposed for the original procedure, with the introduction of FEVAR at each centre being the only constrainer. Inclusion required solely that a patient had undergone a FEVAR and subsequently was re-intervened with a F/BEVAR in FEVAR independent of the number of fenestrations in the original repair. Patients undergoing the original procedure with parallel or branched grafts were excluded. Eight of these patients have been reported separately before.<sup>8–10</sup>

### Data collection

Data were collected retrospectively and/or transferred from local prospective databases following a predefined protocol. Demographic data, past medical history, cardiovascular risk factors, pre-operative comorbidities, imaging, intra- and peri-operative details, and early post-operative morbidity and mortality were recorded. Patients were followed up according to local protocols which included at least a clinical visit and yearly computed tomography angiography. The

data collection and publication were approved by the local committees according to the institutional guidelines.

### Definitions

Outcomes were analysed according to the reporting standards,<sup>11</sup> except that technical success was not precluded by intentional endoleaks deriving from procedure staging or the ones that spontaneously sealed up to the first post-operative computed tomography angiogram (CTA). Technical success was defined as the successful deployment of the stent grafts with patent target vessels and absence of type I or III endoleak at the first post-operative CTA. Clinical success was defined as survival for more than 30 days, absence of aortic re-intervention, as well as absence of aneurysm expansion, graft infection, or thrombosis and aneurysm rupture.<sup>9</sup> Primary clinical success was considered if no re-interventions were needed. Secondary clinical success was assumed when endovascular or open re-interventions were needed to re-establish success of the treatment. Re-interventions included procedures done to correct adverse events or compete unsuccessful intra-operative manoeuvres. Second stage procedures resulting from an intentional decision to stage were not assumed as re-interventions within the initial 30 days but are described separately.

Follow up CTA was done according to each centre's routine. It included a CTA before discharge or within a month and at least yearly thereafter. Branch related instability was defined according to a previously proposed classification by Mastracci *et al.*<sup>12</sup> Aneurysm expansion or shrinkage were assumed whenever the diameter increased or decreased > 10 mm respectively.<sup>4</sup> All imaging was reviewed at each centre by experienced observers according to local routines.

Spinal cord ischaemia (SCI) was defined as any new lower limb neurological deficit not attributable to other pathology. SCI was further classified as paraplegia (complete inability to move the lower limbs) and paraparesis or lower limb weakness (required assistance to stand or to walk).<sup>13</sup> The duration of SCI was considered transient if the neurological deficit resolved within 30 days post-operatively and persistent if it persisted for more than 30 days after the procedure.

Early morbidity was defined as occurring within the first 30 post-operative days. All cause mortality includes both early and late mortality.

### Planning and sizing of fenestrated and branched stent grafts

All patients underwent cardiopulmonary testing with consultation as medical pre-operative work up to decide on suitability for repair. Pre-operative thin slice contrast enhanced CTA was used on a dedicated three dimensional vascular imaging workstation with centreline luminal reconstructions and multiplanar reconstructions. Custom made devices were designed by the graft manufacturer (Cook Medical, Brisbane, Australia) together with the local responsible surgeon.

The proximal landing zone for the F/BEVAR in FEVAR was planned as a  $\geq 20$  mm long segment of the aorta with

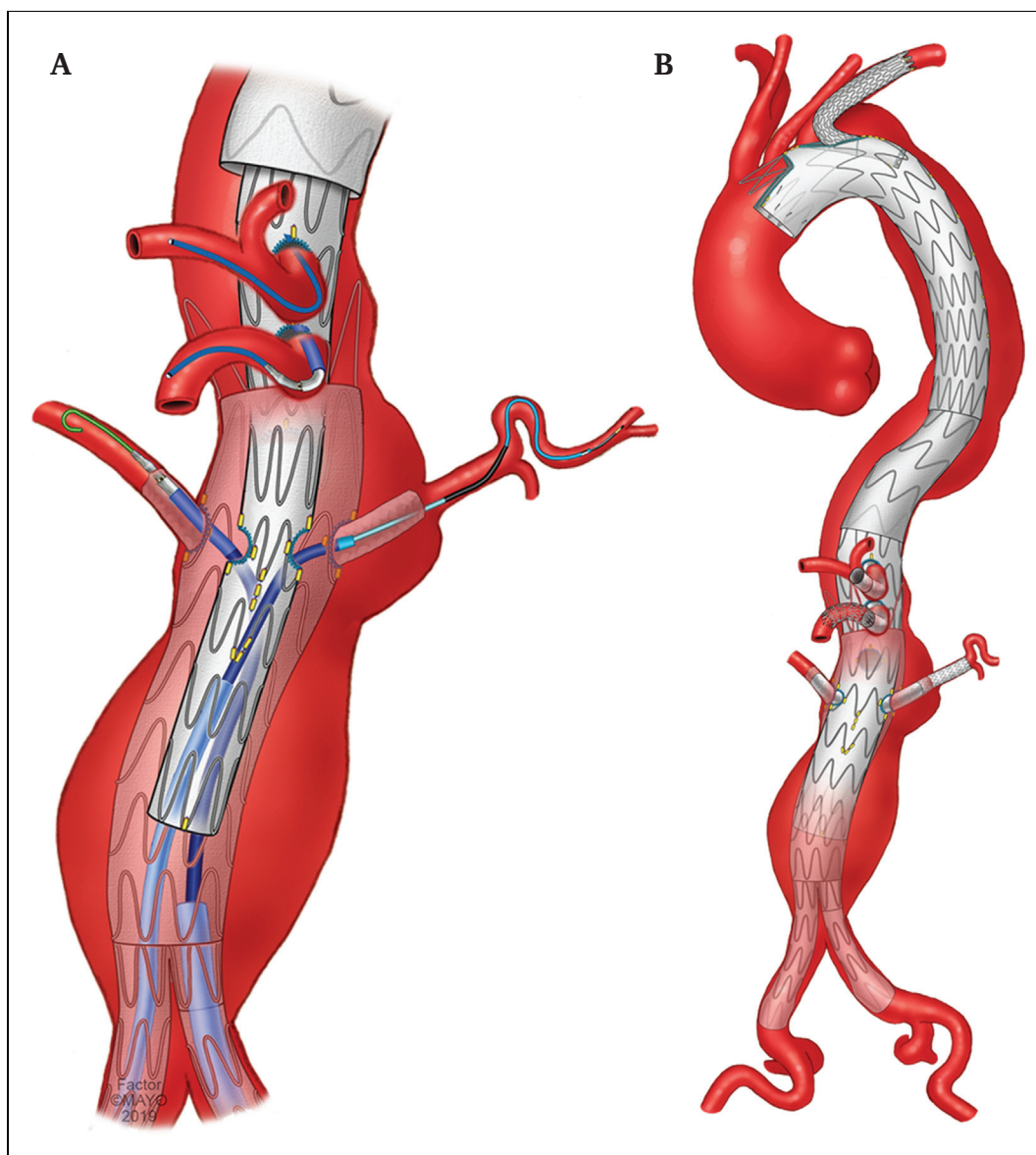
parallel walls and a diameter  $\leq 42$  mm with minimal mural thrombus or calcification. Modular design was used with proximal thoracic components whenever necessary (Fig. 1). Patent aortic branches within the renovisceral segment were incorporated in a tubular component with fenestrations and/or branches. Reinforced fenestrations and/or inner-outer or inner branches were selected depending on the luminal diameter and orientation of the target vessels and original fenestrations. A preloaded delivery system, low profile and proximal access scallops were used when deemed necessary.

#### Procedural details

All procedures were performed in hybrid theatres under general anaesthesia. Intra-operative fusion imaging and CO<sub>2</sub>

contrast were used according to local routine. Each centre used their standardised spinal cord ischaemia prevention protocols which included motor evoked potential (MEPs) monitoring or spinal near infrared spectroscopy. In patients receiving branched grafts where MEPs were used to monitor spinal cord function, a 15 minute balloon occlusion test was done in the last branch.

The steps of the FEVAR procedure have been described widely previously.<sup>14</sup> Distal component and iliac extension limbs were implanted as needed with immediate closure of the femoral accesses. When branch cuffs were incorporated in the design, the TV's were catheterised and bridged from a high brachial or axillary arterial access. This was done by the end of the procedure using either self or balloon



**Figure 1.** Failing fenestrated endovascular aneurysm repair (FEVAR) that required a new four fenestrated FEVAR (F/BEVAR in FEVAR) and a proximal extension up to the aortic arch. (A) All the target vessels catheterised with the F/BEVAR in FEVAR still partially constricted. (B) Final result with proximal seal in the distal arch with a custom made device incorporating a retrograde branch for left subclavian artery and scallop for the left common carotid.

expandable peripheral covered stents according to local preference. In case of self expanding stents, balloon expandable stents were liberally placed for reinforcement at the level of the original FEVAR fenestration or crossing of previous aortic bare stents to prevent compression. Completion intra-operative non-contrast enhanced cone beam computed tomography (CT) was used according to local preference.

### Statistical analysis

Continuous data were reported as median and interquartile range, and categorical data as either absolute numbers or percentages. Survival was estimated with life tables according to Kaplan–Meier and presented as percentage with standard error. Statistical analysis was done with SPSS Version 26.0 software (IBM Corporation, Armonk, NY).

## RESULTS

### Patient characteristics

Eighteen male patients (76 years old; range 69 – 78 years) underwent F/BEVAR in FEVAR between November 2012 and July 2019 to salvage a FEVAR with a failing proximal sealing zone that had been implanted between January 2007 and July 2018. During the period from January 2007 to July 2019, 2805 FEVAR were done at the eight institutions (0.64% receiving F/BEVAR in FEVAR). The median time from the initial repair to diagnosis of the failure was 46 (25 – 95) months while the F/BEVAR in FEVAR was done 53 (29 – 103) months post-operatively. One open conversion of failed FEVAR was done during the study period due to graft infection. Patient characteristics are detailed in Table 1.

Thirteen (72%) of the initial FEVARs incorporated the distal part of the renovisceral segment with a graft with two fenestrations and one scallop being the most common configuration (12 patients, Fig. 2). Mean target vessels in the initial FEVAR was two (two or three) and in two cases the procedures had been performed urgently. Table 2 details the characteristics of all the initial FEVARs, while Table S3 shows the configuration of each FEVAR and F/BEVAR in FEVAR.

Indication for F/BEVAR in FEVAR was as a type Ia endoleak in eight cases, a type Ia endoleak combined with graft migration in eight cases, one graft migration without endoleak and one migration with significant proximal aortic expansion.

The new F/BEVAR in FEVAR involved all patent renovisceral arteries, i.e., four target vessels in 14 (78%) patients, three target vessels in three (17%) and two in one (5%) patient who was already on dialysis. A standard preloaded delivery system with a proximal bare stent was used in eight (44%) patients and a modified preloaded delivery system without bare stent in four (22%). A low profile stent graft was used in seven (39%) patients. Additional proximal standard thoracic components were used in 10 (56%) patients when the fenestrated/branched component did not achieve a proximal seal. The distal seal was achieved either

with a straight (14 [78%] patients) or bifurcated graft (three standard devices (17%) and one short body bifurcated graft with inverted contralateral limb).

### Intra- and peri-operative results

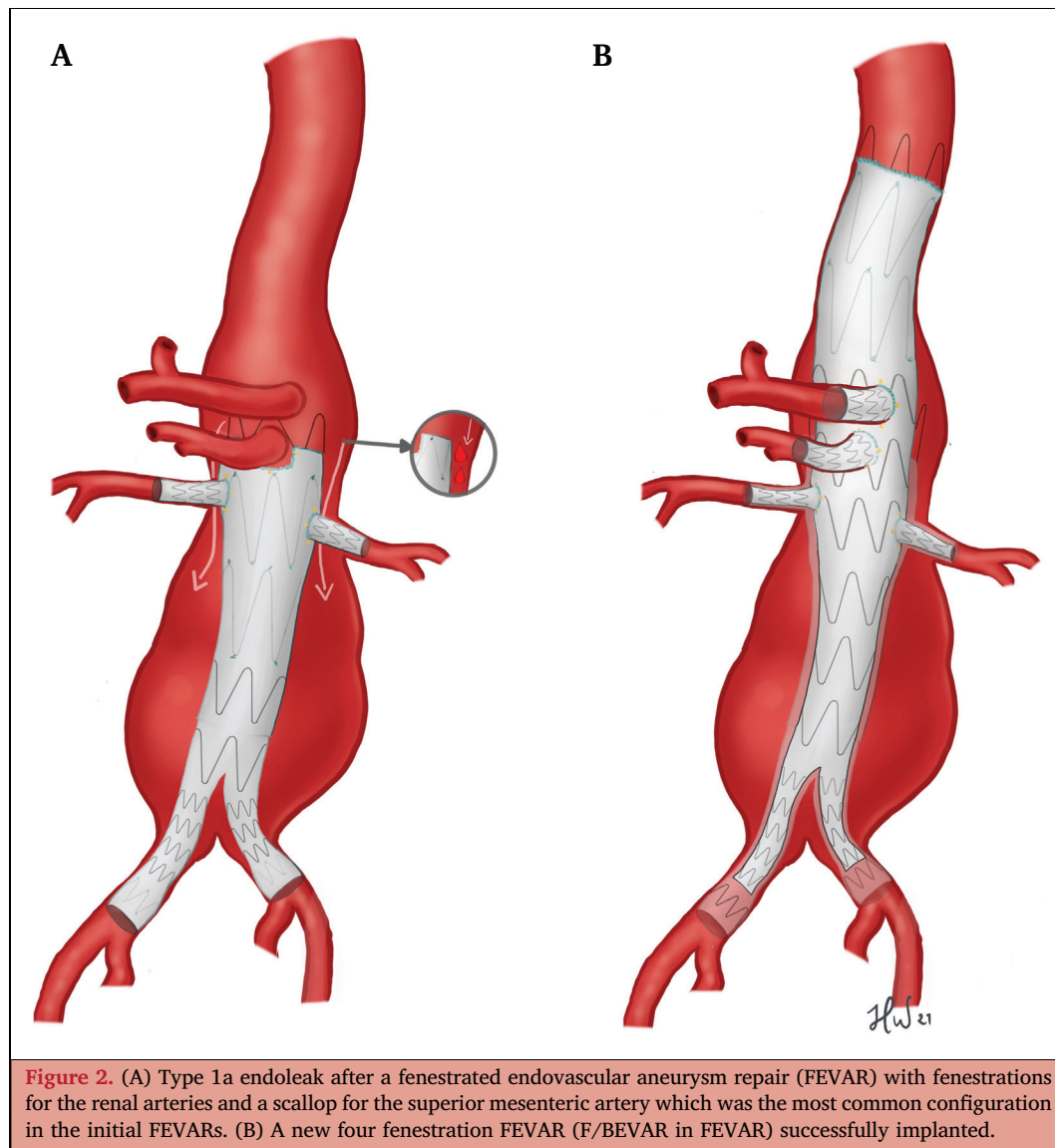
Intra-operative fusion imaging was used in 14 (78%) patients and CO<sub>2</sub> contrast in five (28%). Two (11%) patients had the proximal sealing in zone 3, six (33%) in zone 4, and 10 (56%) in zone 5. Upper extremity access was used in 13 patients (72%): seven (39%) from the right arm, four (22%) from the left, and two (11%) had bilateral upper extremity access. Median total aortic coverage length was 199 (172 – 205) cm. A cone beam CT was done on completion of the F/BEVAR in FEVAR in 10 (56%) cases. Details regarding the procedures can be found in Table 3.

Technical success was achieved in 15 (83%) cases. In one patient it was not possible to bridge a branch cuff to the left renal artery intra-operatively. This was done on a later occasion through an open retrograde access. In another patient a left renal artery branch was successfully bridged but had to be embolised later the same day due to intracapsular bleeding of the kidney. In another patient the concomitant bilateral common iliac extension due to type Ib endoleaks was only successful on one side. It was decided to perform an extension to the external iliac artery at a later date to limit the risk of spinal cord ischaemia but the patient has been refusing it for 18 months. Three patients had staged procedures. This was done in one case where the bifurcated graft was inserted at a later date to shorten a long procedure. In the other two patients staging was decided intra-operatively by leaving the coeliac branch unbridged. The reason for this decision was the loss of MEPs in a patient undergoing a thoraco-abdominal type II repair and in the other it was aimed at shortening a procedure complicated by an iatrogenic perforation of left subclavian artery that was covered with a stent graft. The coeliac branches were bridged two and eight days later without further endoleak or neurological complications.

**Table 1. Clinical characteristics of 18 patients undergoing redo fenestrated/branched endovascular aneurysm repair (F/BEVAR) to rescue failed fenestrated endografts**

Patient characteristics	Patients (n = 18)
Male gender	18
Age at the time of re-F/BEVAR – y	76 (69–78)
Aneurysm diameter – mm	63 (56–69)
<b>Comorbidity</b>	
Heart disease	3
Diabetes mellitus	1
COPD	9
Renal insufficiency	4
Hypertension	14
Stroke	3
Coronary artery disease	11

Data are presented as n or median (interquartile range). COPD = chronic obstructive pulmonary disease.



**Figure 2.** (A) Type 1a endoleak after a fenestrated endovascular aneurysm repair (FEVAR) with fenestrations for the renal arteries and a scallop for the superior mesenteric artery which was the most common configuration in the initial FEVARs. (B) A new four fenestration FEVAR (F/BEVAR in FEVAR) successfully implanted.

**Table 2.** Initial details of fenestrated/branched endovascular aneurysm repairs (F/BEVAR) of 18 patients demanding redo F/BEVAR for failed endografts

Details	Patients (n = 18)
<i>Initial F/BEVAR</i>	
1 fenestration	1
2 fenestrations + 1 scallop	12
3 fenestrations + 1 scallop	5
Time to F/BEVAR in FEVAR – mo	53 (29–103)
<i>Type of aortic graft</i>	
ZFEN	17
Anaconda FEVAR	1
<i>Number of target vessel with fenestrations</i>	
1	1
2	11
3	6
Urgent procedures	2

Data are presented as n or median (interquartile range).

The length of post-operative hospital stay was eight (6 – 13) days, all patients survived for more than 30 days and there were no in hospital deaths. As mentioned above, two early re-interventions were required besides the two second stage coeliac branch bridgings. One renal branch was embolised due to intracapsular bleeding from left kidney (same day as the primary surgery) and one renal branch was bridged through an open retrograde approach (two days post-operatively).

Two patients developed SCI post-operatively. One was a transient paraparesis in a patient with a previous history of spinal stenosis and the other was as a permanent paraplegia. In this elective case the repair started at zone four with a total aortic coverage of 226 mm. Three patients developed post-procedural acute kidney injury. One of these was the patient undergoing renal artery branch embolisation due to intracapsular bleeding while another one was the one developing permanent paraplegia. In the third patient it was most likely a contrast induced injury since

**Table 3. Details for the fenestrated/branched endovascular aneurysm repair (F/BEVAR) in FEVAR procedure in 18 patients**

	Patients (n = 18)
Operation time – min	238 (204–344)
Fluoroscopy time – min	97 (63–131)
Dose area product – Gy.cm <sup>2</sup>	591.5 (141.2–2679.5)
Contrast volume – mL	110 (84–133)
<b>FEVAR configuration</b>	
4 fenestrations	3
3 fenestrations	2
3 fenestrations/1 branch	2
2 fenestrations/2 branches	6
1 fenestration/3 branches	3
T branch	2
Proximal component/TEVAR	10
<b>Proximal landing zone</b>	
Zone 3	2
Zone 4	6
Zone 5	10
<b>Distal component</b>	
Tubular straight extension graft	14
Regular distal unibody	3
CMD bifurcated with inverted limb	1

Data are presented as *n* or median (interquartile range). CMD = custom manufactured device; TEVAR = thoracic endovascular aneurysm repair.

both renal arteries were patent with no apparent renal emboli.

### Follow up

Median CT follow up was 18 (2 – 39) months. Thirteen (72%) patients had primary clinical success throughout follow up. Three (17%) patients required late re-interventions. Two patients were classified as persistent clinical failures for the purpose of this study. In one a renal artery branch had been embolised despite the aneurysm being well excluded as mentioned above. The other one repeatedly refused treatment of a type Ib endoleak that rerequired an intra-operative common iliac extension. Secondary clinical success was achieved in 16 (89%) patients.

In one patient, clinical success was only achieved 15 months post-operatively when the second stage was performed with placement of the distal bifurcated component. The delay was due to unrelated health issues and patient preference. Two other patients required late re-interventions. One that had originally undergone F/BEVAR in FEVAR due to an overt type Ia endoleak combined with FEVAR migration, later had a type II endoleak with expansion. Translumbar embolisation was planned but he presented acutely with abdominal pain and an infection of unknown focus. Open resection of the aneurysm sac with ligation of the lumbar arteries was performed. The bacterial cultures from the aneurysm were negative and the aneurysm remained well excluded until the patient's death from malignancy nine months later. The remaining patient required a total of four re-interventions after a F/BEVAR in

FEVAR that had been done with a renovisceral tubular component until clinical success was achieved. Initially, a high pressure PTA of the left renal was done to solve a distal endoleak three months post-operatively. Then, a type II endoleak was embolised after four more months but the patient presented with aneurysm rupture due to a type III endoleak after three more months. This was caused by separation between the fenestrated and initial bifurcated device which had not been noted during the regular follow up imaging. An uneventful acute re-intervention with a tubular aortic stent graft was done. Clinical success was eventually achieved when the coeliac branch was relined due to a type III endoleak after six more months.

Primary clinical success at 12 and 24 months were  $58 \pm 16\%$  and  $58 \pm 16\%$  while the corresponding secondary clinical success was  $84 \pm 11\%$  and  $84 \pm 11\%$  (Figure S1).

Clinical follow up duration was 27 (7 – 39) months, with an overall survival at 12 and 24 months of  $82 \pm 9\%$  and  $70 \pm 11\%$ , respectively. No aneurysm related death occurred but there were seven late non-aneurysm related deaths after 25 (7 – 45) months (Figure S2).

### DISCUSSION

This study shows the feasibility and acceptable outcomes of F/BEVAR in FEVAR after failure of the proximal sealing zone of a previous FEVAR. The number of patients included is not great, although multiple high volume centres participated. This shows that F/BEVAR in FEVAR is very rarely used, which may be the result of the combination of several factors. The patients that initially underwent FEVAR and have the longest follow up were mostly unfit for open repair. Their expected survival may therefore be limited,<sup>15,16</sup> which allows the repair to outlive them, or they may refuse or become too frail to allow a major re-intervention such as F/BEVAR in FEVAR. This last concept is reinforced by similar findings seen for patients undergoing infrarenal EVAR.<sup>17</sup> More importantly, the failure of the proximal seal after FEVAR appears to be rare when an adequate sealing zone is chosen for the original FEVAR<sup>18</sup> and most centres are currently liberal in having the repair incorporating all the renovisceral segment with 1.5 to two covered stents extending above the most cranial fenestration in the initial repair. This has been shown not to increase the risks significantly<sup>19</sup> at the same time that it allows a future proximal extension to be done with a simple TEVAR instead of requiring a very complex F/BEVAR in FEVAR when only a part of the renovisceral segment was included.

The F/BEVAR in FEVARs were done with no deaths and acceptable major post-operative complications. These results were achieved in centres already having large experience with primary and redo FEVAR, which may have compensated for the complexity of the situation. This complexity may justify the long procedure times that at times also required interruption of some procedures to continue later. This type of staging was done without apparent adverse events and appears to be a safe strategy. However, spinal cord ischaemia remains a concern

considering the extensive aortic coverage required and that it still occurred despite all centres having well established spinal cord protection protocols. Another concern is the non-dismissible mortality during follow up. Even if this was non-aneurysm related, it still suggests a need to improve the selection of the patients that will benefit the most from a major re-intervention such as a F/BEVAR in FEVAR.

One of the most important and difficult issues when facing a FEVAR with a failing proximal seal is the planning of the new device. These difficulties are expressed by the variation of the configurations used in the F/BEVAR in FEVAR grafts. Even if some of this variation can be due to local preferences, much derives from the diverse anatomic restraints. The protrusion into the aortic lumen of the mating stents from the original fenestrations may reduce the free aortic lumen, especially if the original F/BEVAR had a small diameter at this level. In these circumstances, the flexibility that is otherwise given by standard internal–external branches disappears since the inner edge of the target vessel stents would come against the tubular part of the new graft. This may be compensated by the use of inner branches instead that have their outer opening in an indentation of the graft. However, even these have limitation of available aortic lumen and are currently only caudally oriented which may be of limited use in cranially oriented target vessels. Cranially oriented or bidirectional branches may potentially confer some advantage in these circumstances, but these solutions still need further development or better understanding of their long term results. Independently, if a branch is used, the restricted space between the new and old aortic grafts should make the reinforcement with balloon expandable stents crucial to avoid compressions. Conversely, the alternative to the use of branches is the incorporation of fenestrations in the F/BEVAR in FEVAR design. These have well established results, especially for the renal arteries.<sup>20</sup> Moreover, they can currently be incorporated in preloaded delivery systems which allows the reduction of the profile of the introducer sheath on the contralateral side, improving lower limb perfusion during these long procedures and thereby potentially reducing the risks of complications.<sup>21</sup> However, even the planning of the placement of the fenestrations in F/BEVAR in FEVAR may still be difficult due to the aforementioned protrusion and possible angulation in the anteroposterior direction of the original mating stents. Moreover, in such cases, the catheterisation can also be very demanding since there is very limited room for adjusting the position of the F/BEVAR in FEVAR in terms of height and rotation after the initial deployment. The use of double diameter reducing ties can give some extra room but the aggressive re-flaring of the original mating stents before the insertion of the F/BEVAR in FEVAR may be very useful. The guidewires can even be left in place to facilitate the visualisation of the original target vessel mating stents, which becomes hard among the multitude of graft makers. Fusion imaging guidance is also an important adjunct for an easier identification of the inner edge of the original stents. Another variation was the distal extension of the grafts,

where relining of the bifurcated component was not universally done. This needs to be decided on a patient specific basis, but the large numbers of grafts already in place makes the identification of impending separation of components difficult as illustrated in one of the patients. So, relining with a new bifurcated graft should be done liberally. Despite the variations in graft planning, re-interventions and clinical success rates were similar to that reported for primary FEVAR, including target vessel instability that did not develop post-operatively. This suggests that the difficulties of F/BEVAR in FEVAR are mostly technical and that the results appear to be satisfactory once technical success is established. Furthermore, future technical developments such as the more versatile grafts with for instance bidirectional branches may allow the improvement of the results.

There are some limitations to this study that need to be recognised. This study reports a limited and heterogeneous population, which limits the generalisation of the conclusion until further confirmation. Moreover, only one technical solution for this complex situation is assessed with limited follow up and the applicability of other solutions is not included. A comparative study would be difficult to perform given the aforementioned rarity of the situation and the constant development of new technical alternatives. An analysis of the incidence of the failure of the proximal seal after the original FEVAR and of the subsequent selection for F/BEVAR in FEVAR would be interesting. However, the retrospective design together with the fact that some of the patients had had the original FEVAR done in other institutions made it impossible. This should therefore be approached in a separate study, the same being true for the cost effectiveness of aneurysm repair in these patients.

In conclusion, F/BEVAR in FEVAR is rarely needed and technically demanding but not beyond the therapeutic spectrum. The results are very promising but need to be confirmed by larger series with longer follow up. Improvements are needed to minimise serious complications and the need for re-interventions, as well as optimising patient selection to identify the patients that will benefit the most from F/BEVAR in FEVAR in the long term.

#### CONFLICT OF INTEREST

S.H.: Consultant for Cook Medical, Bentley, GE Healthcare; D.A. and M.C.: educational grants from Cook Medical and Atrium-Maquet; G.O.: consulting and grants from Cook Medical, W.L. Gore and GE Healthcare (all paid to the institution with no personal income); A.K.: Consultant Cook Medical; E.V. and N.V.D.: Consulting and IP with Cook Medical. Other authors declare no conflict of interest.

#### FUNDING

This study was supported by Hulda Almroth Foundation, the Skåne University Hospital (SUS) Research Grants and the Governmental funding of clinical research within the National Health Services (ALF).

## ACKNOWLEDGEMENTS

Centre contributions: Paris (two patients), Lille (two patients), Birmingham (three patients), Hamburg (two patients), Nuremberg (two patients), Houston (one patient), Perugia (one patient), Malmö (five patients).

## APPENDIX A. CONTRIBUTORS

Pablo Marqués, Emanuel Ramos Tenorio, Martin Claridge, Francesco Casali, Nikolaos Tsilimparis, Jonathan Sobocinski, Athanasios Katsargyris.

## APPENDIX B. SUPPLEMENTARY DATA

Supplementary data to this article can be found online at <https://doi.org/10.1016/j.ejvs.2021.06.038>.

## REFERENCES

- Spanos K, Antoniou G, Giannoukas AD, Rohlfs F, Tsilimparis N, Debus SE, et al. Durability of fenestrated endovascular aortic repair for juxta-renal abdominal aortic aneurysm repair. *J Cardiovasc Surg (Torino)* 2018;**59**:213–24.
- Dossabhoy SS, Simons JP, Diamond KR, Flahive JM, Aiello FA, Arous EJ, et al. Reinterventions after fenestrated or branched endovascular aortic aneurysm repair. *J Vasc Surg* 2018;**68**:669–81.
- O'Callaghan A, Greenberg RK, Eagleton MJ, Bena J, Mastracci TM. Type Ia endoleaks after fenestrated and branched endografts may lead to component instability and increased aortic mortality. *J Vasc Surg* 2015;**61**:908–14.
- Wanhainen A, Verzini F, Van Herzele I, Allaire E, Bown M, Cohnert T, et al. European Society for Vascular Surgery (ESVS) 2019 clinical practice guidelines on the management of abdominal aorto-iliac artery aneurysms. *Eur J Vasc Endovasc Surg* 2019;**57**:8–93.
- Troisi N, Donas KP, Austermann M, Tessarek J, Umscheid T, Torsello G. Secondary procedures after aortic aneurysm repair with fenestrated and branched endografts. *J Endovasc Ther* 2011;**18**:146–53.
- d'Utra G, O'Brien N, Maioli F, Perot C, Bianchini A, Maurel B, et al. Challenging treatment of a secondary endoleak in a fenestrated endograft. *J Endovasc Ther* 2010;**17**:458–61.
- Ritter JC, Stanley BM. The "fenestrated inside fenestrated" stent graft solution for therapy-resistant type Ia endoleak after fenestrated endovascular aortic aneurysm repair. *J Vasc Surg* 2014;**59**:814–6.
- Spanos K, Tsilimparis N, Heidemann F, Rohlfs F, Behrendt CA, Debus ES, et al. Technique for fenestrated stent-graft implantation as a proximal extension to a previous fenestrated endovascular repair for abdominal aortic aneurysm. *J Endovasc Ther* 2018;**15**:16–20.
- Katsargyris A, Oikonomou K, Kouvelos G, Mufty H, Ritter W, Verhoeven ELG. Comparison of outcomes for double fenestrated endovascular aneurysm repair versus triple or quadruple fenestrated endovascular aneurysm repair in the treatment of complex abdominal aortic aneurysms. *J Vasc Surg* 2017;**66**:29–36.
- Hongku K, Resch T, Sonesson B, Dias NV. Mid-term results of fenestrated and of branched aneurysm repair of previous failed fenestrated EVAR. *Ann Vasc Surg* 2020;**67**:35–42.
- Chaikof EL, Blankensteijn JD, Harris PL, White GH, Zarins CK, Bernhard VM, et al. Reporting standards for endovascular aortic aneurysm repair. *J Vasc Surg* 2002;**35**:1048–60.
- Mastracci TM, Greenberg RK, Eagleton MJ, Hernandez AV. Durability of branches in branched and fenestrated endografts. *J Vasc Surg* 2013;**57**:926–33.
- Sobel JD, Vartanian SM, Gasper WJ, Hiramoto JS, Chuter TA, Reilly LM. Lower extremity weakness after endovascular aneurysm repair with multibranched thoracoabdominal stent grafts. *J Vasc Surg* 2015;**61**:623–8.
- Georgiadis GS, van Herwaarden JA, Saengprakai W, Georgakarakos EI, Argyriou C, Schoretsanitis N, et al. Endovascular treatment of complex abdominal and thoracoabdominal type IV aortic aneurysms with fenestrated technology. *J Cardiovasc Surg (Torino)* 2017;**58**:574–90.
- Kristmundsson T, Sonesson B, Dias N, Tornqvist P, Malina M, Resch T. Outcomes of fenestrated endovascular repair of juxtarenal aortic aneurysm. *J Vasc Surg* 2014;**59**:115–20.
- Mohamed N, Galyfos G, Anastasiadou C, Sachmpatzidis I, Kikiras K, Papapetrou A, et al. Fenestrated endovascular repair for pararenal or juxtarenal abdominal aortic aneurysms: a systematic review. *Ann Vasc Surg* 2020;**63**:399–408.
- Abdulrasak M, Sonesson B, Singh B, Resch T, Dias NV. Long-term outcomes of infrarenal endovascular aneurysm repair with a commercially available stent graft. *J Vasc Surg* 2020;**72**:520–30.
- Juszczak MT, Murray A, Koutsoumpelis A, Vezzosi M, Mascaro J, Claridge M, et al. Elective fenestrated and branched endovascular thoraco-abdominal aortic repair with supraceliac sealing zones and without prophylactic cerebrospinal fluid drainage: early and medium-term outcomes. *Eur J Vasc Endovasc Surg* 2019;**57**:639–48.
- Mastracci TM, Eagleton MJ, Kuramochi Y, Bathurst S, Wolski K. Twelve-year results of fenestrated endografts for juxtarenal and group IV thoracoabdominal aneurysms. *J Vasc Surg* 2015;**61**:355–64.
- Mastracci TM, Carrell T, Constantinou J, Dias N, Martin-Gonzalez T, Katsargyris A, et al. 's Choice – Effect of branch stent choice on branch-related outcomes in complex aortic repair. *Eur J Vasc Endovasc Surg* 2016;**51**:536–42.
- Maurel B, Delclaux N, Sobocinski J, Hertault A, Martin-Gonzalez T, Moussa M, et al. The impact of early pelvic and lower limb reperfusion and attentive peri-operative management on the incidence of spinal cord ischemia during thoracoabdominal aortic aneurysm endovascular repair. *Eur J Vasc Endovasc Surg* 2015;**49**:248–54.