

**Original article: Bronchopulmonary and vascular anomalies are frequent in children  
with oesophageal atresia**

**Stephanie Lejeune<sup>1,2</sup>**

**Armelle Le Mee<sup>1</sup>**

**Laurent Petyt<sup>3</sup>**

**Antoine Hutt<sup>4</sup>**

**Rony Sfeir<sup>2</sup>**

**Laurent Michaud<sup>2†</sup>**

**Pierre Fayoux<sup>2</sup>**

**Antoine Deschildre<sup>1,2</sup>**

**Frederic Gottrand<sup>2</sup>**

**Caroline Thumerelle<sup>1,2</sup>**

<sup>1</sup>Pediatric Pulmonology and Allergy Department, Pole enfant, Jeanne de Flandre Hospital, CHU Lille, Univ. Lille, France.

<sup>2</sup>CRACMO: Centre de Référence des Affections Chroniques et Malformatives de l'œsophage, Reference Centre for Rare Oesophageal Diseases, CHU Lille, Univ. Lille, LIRIC UMR 995, Lille, France

<sup>3</sup>Department of Paediatric Imaging, Hospital Jeanne de Flandre Hospital, CHU Lille, Univ. Lille, France.

<sup>4</sup>Department of Thoracic Imaging, Hospital Calmette, CHU Lille, Univ. Lille, France

**Short title: Intrathoracic anomalies in oesophageal atresia**

**Finance**

This study did not receive any specific funding.

**Conflicts of interest**

The authors have no conflicts of interest to declare.

**This study was presented at the** Francophone Hepato-gastroenterology and Digestive

Oncology Congress, March 2019, and the Francophone Paediatric Pulmonology and Allergology Congress, November 2014.

**Corresponding author:** Caroline Thumerelle, Paediatric Pulmonology and Allergy Department, Pole enfant, CRACMO Reference Centre for Rare Oesophageal Diseases, Jeanne de Flandre Hospital, CHU Lille and Universite Nord de France, F-59037 Lille, France.  
Telephone number: 0033320445072 - Fax number: 0033320444107

caroline.thumerelle@chru-lille.fr

**Word count: 3,091**

**Number of tables: 2**

**Number of figures: 4**

## **ABBREVIATIONS**

CT, Computed tomography.

## **ABSTRACT**

**Aim:** Oesophageal atresia is frequently associated with other malformations and our study aim was to use computed tomography (CT) to describe intrathoracic malformations in patients with this condition.

**Method:** This was retrospective study of children with oesophageal atresia who were born in 1996-2013 and followed up at the French reference centre for rare oesophageal diseases at the University of Lille. CT scans were available for 48 of the 234 patients during follow-up visits and these were reviewed by a thoracic radiologist.

**Results:** More than two third of the scans were performed to explore persistent respiratory symptoms. Thirteen percent of patients had a pulmonary malformation: four lobar agenesis, one right pulmonary aplasia, and one congenital cystic adenomatoid malformation. CT permitted diagnosis of an unexpected thoracic malformation among 27%: four lobar agenesis, six arteria lusoria, five persistent left superior vena cava, one partial anomalous pulmonary venous return, and confirmed diagnosis of suspected malformations among 10%: one congenital cystic adenomatoid malformation, one pulmonary hypoplasia, two right-sided aortic arch, and one communicating bronchopulmonary foregut malformation.

**Conclusion:** Intrathoracic anomalies were frequently associated with oesophageal atresia, and contrast-enhanced chest CT scans should be performed on patients with persistent respiratory symptoms.

**KEYWORDS:** congenital malformations, diagnostic imaging, oesophageal atresia, thoracic malformations, contrast-enhanced CT scan.

## KEY NOTES

- Oesophageal atresia is frequently associated with other malformations and we analysed the contribution of chest computed tomography (CT) scans to explore intrathoracic malformations.
- In 48 children, we diagnosed an unexpected thoracic malformations in 13% and confirmed a suspected malformation in 10%, including one congenital cystic adenomatoid malformation and one pulmonary hypoplasia.
- Contrast-enhanced chest CT scans should be performed in oesophageal atresia patients to explain persistent respiratory symptoms.

## INTRODUCTION

Oesophageal atresia is a rare congenital anomaly, with an incidence of one in 2,500 to 3,500 births. It is associated with a tracheoesophageal fistula in about 90% of cases, namely Ladd classification types II, III, IV, and V (1,2). Various associated anomalies have been reported, with one or more associated malformation in 50-62% of cases (1-3). These associated anomalies mostly involve the respiratory tract, cardiovascular system, skeleton, gastrointestinal tract and, or, urogenital tract. In many cases there are more than one anomaly, as seen by patients' vertebral defects, anal atresia, cardiac defects, tracheo-oesophageal fistula, renal anomalies, and limb abnormalities (VACTERL) associations (1,3). Specific associations between oesophageal atresia and respiratory tract malformations have been described (4-6). Furthermore, rare bronchopulmonary malformations, including communicating bronchopulmonary foregut malformations, which seem to be associated with oesophageal atresia, occur on a relatively frequent basis (7,8).

Chest computed tomography (CT) scans of patients with oesophageal atresia are performed in numerous contexts: preoperative evaluations, including assessment before aortopexy, when there are persistent respiratory symptoms and in cases with postoperative complications (9-11). Contrast-enhanced chest CTs provide precise anatomical descriptions of the airways, lung parenchyma and mediastinal vascularisation and can lead to diagnoses of thoracic abnormalities, including tracheobronchial and pulmonary malformations.

The aim of our study was to analyse the contribution of chest CT to the diagnosis of bronchopulmonary and mediastinal vascular anatomical malformations in children with oesophageal atresia treated at our centre. This paper describes the associated malformations, and compares our findings with the existing literature.

## **PATIENTS AND METHODS**

Our observational, retrospective, descriptive study included all 234 patients with oesophageal atresia born between 1996 and 2013, who were followed at our reference centre for rare oesophageal diseases at the University of Lille, France. We focused on the 48 patients who underwent at least one chest CT during follow up available for interpretation.

The patients' past clinical history was collected and oesophageal atresia was based on the Ladd classification (2). The existence of an associated chromosomopathy was noted. As recommended, all children diagnosed with oesophageal atresia underwent the following exams: chest radiography, echocardiography, abdominal ultrasound and spinal radiography (1). We noted cases of associated congenital anomalies and whether they were part of a VACTERL association. The patients' past surgical history was also collected when it was available, namely: oesophageal atresia repair, cardiac surgery, aortopexy, fundoplication and laryngotracheal endoscopy results. Finally, we noted cases of tracheomalacia diagnosed with laryngotracheal endoscopy and any history of tracheoesophageal fistula recurrences.

All chest CT scans were collected and re-analysed by a certified thoracic radiologist with 26 years of experience. If multiple CT scans were available for a child, the exam that provided the best quality was retained and analysed. The exam indications were classified into six categories: persistent respiratory symptoms, lung evaluation in tracheoesophageal fistula recurrence, preoperative assessment before aortopexy, evaluation of tracheal stenosis, complications following oesophageal atresia repair, cardiovascular indications and other indications. With the exception of tracheal bronchus, anatomic variants of the tracheobronchial tree were not retained for analysis. We reported cases of tracheal stenosis with regard to tracheal anomalies,. We also reported suspicion of tracheomalacia on CT scans, assessed by indirect signs in free-breathing children. This involved visualisation of a tracheal compression by the aorto innominate complex (11).

Aortic anomalies were searched for in all cases and were described according to the position of the aortic arch. In patients with contrast-enhanced CTs, we reported cases of arteria lusoria: left arch aberrant right subclavian artery. We also reported other vascular anomalies

of the pulmonary veins: anomalous venous return and systemic veins, namely the persistent left superior vena cava (12).

The study was approved by the French Data Protection Commission (CNIL: National Commission on Informatics and Liberties; number DEC16-230). All the data were used anonymously and informed consent was not required.



## RESULTS

### Sample characteristics

There were 234 patients with oesophageal atresia who were born between 1996 and 2013 and followed at our specialist centre. Of these 49 (21%) had undergone at least one chest CT during their follow-up visits (Fig. 1). One CT scan was unavailable for interpretation and this meant that the analyses were based on 48 patients (56% boys). There was one missing value for five of the six associated malformations because the child was not born in our centre and was followed up in the later years.

Table 1 lists the main sample characteristics and shows that 39/48 (81%) had Ladd classification type III oesophageal atresia. A blood karyotype was performed in 24 patients and two were diagnosed with a chromosomal anomaly: one with 22q11.2 deletion and one with chromosome 15q duplication. We found that 13/48 (27%) patients had a VACTERL association. In addition, 15/47 (32%) patients had congenital heart disease diagnosed with echocardiography. These included three patients with complex congenital heart disease, seven with ventricular septal defects, three with atrial septal defects, one case of associated ventricular septal defect with atrial septal defect, two cases of coarctations of the aorta and one with pulmonary valvular stenosis. Those with complex congenital heart disease included one tetralogy of Fallot, one double outlet right ventricle with a right aorta with a diagnosis of 22q11.2 deletion and one case of associated atrial septal defect and right pulmonary artery hypoplasia. There were 14/48 (29%) patients with a congenital disorder of the urogenital system, including nine high-grade vesicoureteral reflux, two multicystic dysplastic kidneys, one unilateral renal agenesis and two other malformations. Just under a third, 14/47 (30%), of the patients had an associated costovertebral anomaly: six anomalies of the ribs, seven vertebral malformations and one case of associated vertebral and costal malformations. We found that 6/47 (13%) patients had another malformation of the gastrointestinal tract: three imperforate anuses, one duodenal atresia, one intestinal malrotation and one small bowel atresia. Then there were 4/47 (8%) patients with a laryngeal supraglottic anomaly: one posterior laryngotracheal cleft, one left vocal cord paralysis, one laryngeal hypoplasia and one

laryngocele. Tracheomalacia was noted in 22/30 (73%) of the patients with an available laryngotracheal endoscopy. We also noted that 20/47 (43%) patients had a history of fundoplication, six (13%) of cardiac surgery, and five (10%) of aortopexy.

### **Chest CT analyses**

The median age at the time of the CT was four years and five months (range one day to 16 years and two months). Just under two third, 30/48 (63%), of the exams were performed with contrast administration. The indications for these exams were: exploration of persistent respiratory symptoms for 33/48 (69%), lung evaluation in case of suspicion of tracheoesophageal fistula recurrence for six (13%), preoperative assessment before aortopexy for three (6%) and before congenital tracheal stenosis surgery for three (6%) and complications after oesophageal atresia repair for five (10%). In 7 cases there were multiple reasons. The five cases of complication after oesophageal atresia related to: severe dysphagia for two (4%), mediastinitis after oesophageal atresia repair for three (6%), including one case with severe dysphagia, and preoperative assessment before cardiac surgery for one (2%). One CT scan was performed to investigate an antenatal suspicion of congenital cystic adenomatoid malformation.

### **Lung anomalies**

We found 6/48 (13%) congenital pulmonary malformations including four (8%) lobar agenesis, with two middle lobe agenesis and two middle and upper right lobes agenesis (Fig. 2a). There was also one (2%) right pulmonary aplasia and one (2%) congenital cystic adenomatoid malformation affecting the right middle and lower lobes (Fig. 2b). Both the congenital cystic adenomatoid malformation and the pulmonary hypoplasia were suspected during antenatal follow-up visits. Conversely, the four cases of lobar agenesis were only diagnosed from a CT scan.

### **Mediastinal vascular anomalies**

There were 3/48 (6%) patients who were diagnosed with a right-sided aortic arch (Fig. 2c). Of the 30 patients who underwent a contrast-enhanced CT scan, 14 (29%) had at least one vascular anomaly. There were two (7%) patients with coarctations of the aorta that were

previously diagnosed with echocardiography, which were associated with one partial anomalous pulmonary venous return and one persistent left superior vena cava. In addition, six (20%) had arteria lusoria (Fig. 2d) and five (17%) had persistent left superior vena cava, including two (7%) associated with arteria lusoria.

When we combined the echocardiography and CT results, 7/47 (15%) patients had an isolated vascular anomaly, eight (17%) had isolated congenital heart disease and seven (15%) had an association, including the two cases of coarctation of the aorta.

### **Tracheobronchial tree anomalies**

We found a tracheobronchial anatomical anomaly in 9/48 (19%) patients, including two (4%) right tracheal bronchus and one (2%) communicating bronchopulmonary foregut malformation, which was a combination of oesophageal atresia with the right main stem bronchus originating from the oesophagus (Fig. 2e). There were seven (15%) patients with a tracheal stenosis, which was confirmed with laryngotracheal endoscopy. Of these, five (10%) were post-intubation focal circumferential strictures. A further two (4%) were congenital stenoses: one laryngeal and upper tracheal hypoplasia without complete rings associated with a right tracheal bronchus and one extended tracheal stenosis with complete rings associated with a right bronchus stenosis. No tracheoesophageal fistula recurrence was seen on the CT scans of the six patients who underwent examinations for lung evaluation before surgery for tracheoesophageal fistula recurrence.

Of note, 32/44 (73%) patients with a history of tracheoesophageal fistula associated with oesophageal atresia, had a residual tracheal diverticulum on CT scans. In addition 15/22 (68%) patients with a confirmed diagnosis of tracheomalacia, were suspected by using indirect signs on CT scans.

### **Associations between pulmonary anomalies and other malformations**

The associated pulmonary, vascular, and cardiac malformations are shown in Fig. 3. We found no chromosomal anomalies in the six patients with a congenital pulmonary malformation. All were associated with at least one malformation of another organ system: vascular anomalies in five, congenital heart disease in two, tracheal stenosis in one, vertebral

anomalies in two, and urogenital system anomalies in three. Three patients had a VACTERL association (Table 2). The patient with communicating bronchopulmonary foregut malformations had no other malformations.

### **Associated malformations**

We found that 26/48 (54%) patients did not display any anatomical intrathoracic malformations on their chest CTs and only nine (19%) presented with isolated oesophageal atresia without any other anatomical anomaly. Indeed, six had congenital heart disease without a vascular anomaly, five had a congenital disorder of the urogenital system, eight had an associated costovertebral anomaly and 12 had at least one anatomical malformation involving another organ system.

Of the 33 patients who presented with recurrent respiratory symptoms, 14 (42%) had no malformations on their CT scans and echocardiography. Seven of these also underwent laryngotracheal endoscopy and four of these were diagnosed with a tracheomalacia.

### **Proposed decision tree**

Computed tomography revealed diagnoses of an unexpected thoracic malformation in 13/48 (27%) patients. There were four lobar agenesis, six arteria lusoria and five persistent left superior vena cava, which were associated with arteria lusoria in two cases. There were confirmed diagnoses of suspected associated malformations in five cases (10%): one congenital cystic adenomatoid malformation, one pulmonary hypoplasia, two right-sided aortic arches and one communicating bronchopulmonary foregut malformation.

Based on these results, we have put together a decision tree that describes the indications for CT scans in children with oesophageal atresia (Fig. 4). An initial chest CT should be performed in a patient with oesophageal atresia with contrast administration, if possible, to search for associated vascular malformations.

## DISCUSSION

Our study confirms that oesophageal atresia was frequently associated with other malformations in our cohort. Chest CTs confirmed the diagnosis of associated thoracic malformations in 37% of patients, including 27% who had not been diagnosed with abnormalities following other investigations. CT scans permitted diagnoses of lobar or unilateral pulmonary agenesis in five (10%) patients and a diagnosis of congenital cystic adenomatoid malformation in one (2%).

Because both the oesophagus and respiratory tract derive from the primitive foregut, the association between digestive and respiratory malformations could be linked to a developmental disorder originating with the division of the primitive foregut into the lung bud and oesophagus during the embryonic stage, at weeks 3-4 of gestation (4,5,7). Most previous descriptions of oesophageal atresia cases associated with respiratory anomalies have concerned tracheomalacia (6,11,13).

In previous studies, the prevalence of pulmonary agenesis and aplasia was estimated at one per 15,000 births, with about 300 descriptions of unilateral lung agenesis (5,14-16). These rare congenital malformations differed from each other based on the persistence of a rudimentary bronchus limited to a blind-end pouch, without lung tissue in cases of pulmonary aplasia. Of note, Stark et al combined 28 reported cases of pulmonary hypoplasia or aplasia associated with oesophageal atresia between 1948 and 2005 (5). In previous descriptions of children with pulmonary agenesis or aplasia, associated congenital anomalies were found in more than one case in two, including oesophageal atresia, structural congenital heart diseases, diaphragm defects and limb anomalies (7,8,15,16). Associations between oesophageal atresia and lobar agenesis have previously been described, usually affecting the right upper and middle lobes. There were more frequent in cases of VACTERL associations (7,15). In our study, we found five cases of pulmonary or lobar agenesis in oesophageal atresia patients and four of these were diagnosed based on CT scans. All of these were associated with other anomalies, including two with VACTERL associations. Asymptomatic, lobar agenesis frequently remains undiagnosed throughout childhood in oesophageal atresia

patients and it may also be involved in the development of restrictive ventilatory defects in adults (17).

This paper also describes one case of congenital cystic adenomatoid malformation, suspected before birth and confirmed with a postnatal chest CT scan. This was also associated with multiple malformations and a VACTERL association. To our knowledge, only three similar cases have been reported before and those were all in patients with type III oesophageal atresia (18,19).

In addition, three (6%) of our patients had bronchial anomalies and two (4%) had a right tracheal bronchus. The latter was an anatomic variant that is frequently described in the general population. The estimated frequency ranges from 0.2% for superior lobar bronchi above the carina to 2% for tracheal bronchus as a whole (7,14). Usui et al performed laryngotracheal endoscopy on 32 patients with oesophageal atresia and found a tracheal bronchus in 13% and an anomaly of the tracheobronchial tree in 47%, including the absence of right upper lobar bronchus in 6% (4). In our study, one patient had a communicating bronchopulmonary foregut malformation affecting the whole right lung, also known as oesophageal lung. This highly rare malformation has been reported in about 20 cases in the literature, half of which were associated with oesophageal atresia, consistent with Srikanth's classification type IA (8,20,21).

As a complement to echocardiography, contrast-enhanced CT may provide precise cartography of both the tracheobronchial tree and mediastinal vessels before surgery (22). We found a vascular anomaly in nearly half of the 30 patients who underwent a contrast-enhanced CT: arteria lusoria in 6 cases and a right-sided aortic arch in 3 cases. Most of the descriptions of mediastinal vascular anomalies associated with oesophageal atresia that have been reported in the literature also involved the aortic arch, including cases of double aortic arches (23,24). Arteria lusoria has been previously described in 0.5 to 2% of the general population (25,26) and in around 8% of patients with oesophageal atresia, rising to 58% of patients with an associated long oesophageal defect and tracheoesophageal fistula (23). In addition, the frequency of a right-sided aortic arch in the general population is estimated to be around 0.1

to 0.9% and as high as 2.5 to 13% in patients with oesophageal atresia (1,11,23,24).

One of our patients presented with partial anomalous pulmonary venous return associated with congenital heart disease and lobar pulmonary agenesis and five presented with persistent left superior vena cava. The latter has been the most frequently described intrathoracic venous anomaly in the general population (0.3-2%), with a rate of 10% in patients with congenital heart disease (27) and an even higher frequency in patients with oesophageal atresia. This was illustrated by a study of a select population of 90 children with oesophageal atresia who had at least one other malformation consistent with VACTERL syndrome, including 5.6% who presented with a persistent left superior vena cava (28).

Tracheal anomalies are very frequent in cases of oesophageal atresia with tracheoesophageal fistulas (6,11,13) and can be diagnosed using CT scans, although laryngotracheal endoscopy remains the standard exam (6,13). In our study, some cases of confirmed tracheomalacia and tracheal stenosis were discovered on CT scans. However, CT scans may be useful in cases of tracheal stenosis, to assess the length of stenosis as well as the vascular environment (7,14). The prevalence of tracheomalacia in oesophageal atresia has been reported to range from 65 to 89% in studies, with reported differences between neonates, young children and teenagers (6,11,13). Although CT scans do not provide dynamic analysis, previous studies have shown that tracheomalacia could be suspected in cases with reduced tracheal lumen on end-expiratory images. These were in children able to perform inspiratory and end-expiratory manoeuvres and in young children under general anaesthesia and during passive breath holding (29, 30). Using this dynamic approach, the anatomical changes can be arbitrarily described as mild (50 to 75% reduction), moderate (75 to 90% reduction) or severe (>90%) (30). During free breathing, as in our study, tracheomalacia could be suspected using indirect signs (11). With regard to the recurrences of tracheoesophageal fistula, the standard exam for diagnosis remains methylene blue test during endoscopy. In years to come, high resolution structural magnetic resonance imaging could become a new tool for diagnosing tracheoesophageal fistula, without the associated radiation hazards (30).

Our study had some limitations. First, our sample comprised children who were

severely affected by oesophageal atresia, had a high frequency of associated malformations and who underwent CT scans based on their symptoms and, or, associated conditions. Second, only 62% of the exams were performed with contrast administration and it was likely that this led to underestimating some vascular anomalies. Finally, the exams were performed at different ages, but this did not alter the diagnosis of associated anatomical anomalies.



## **CONCLUSION**

Our study confirms the frequent association of bronchopulmonary and mediastinal vascular anomalies in patients with oesophageal atresia. Chest CT scans enabled us to diagnose unexpected thoracic malformations in 27% of these patients and confirm major associated malformations in 10%. Further studies are needed to assess the prevalence of these associations in unselected populations with oesophageal atresia. In clinical practice, we recommend performing chest CT scans on patients with oesophageal atresia to check for associated multiple malformations, persistent respiratory symptoms or unexplained restrictive syndrome. Due to the high frequency of associated vascular anomalies, we propose that contrast-enhanced chest CT scans should become the initial exam of choice.

## REFERENCES

1. Ladd WE, Swenson O. Esophageal Atresia and Tracheo-esophageal Fistula. *Ann Surg* 1947; 125: 23-40.
2. Sfeir R, Bonnard A, Khen-Dunlop N, Auber F, Gelas T, Michaud L, et al. Esophageal atresia: data from a national cohort. *J Pediatr Surg* 2013; 48: 1664-9.
3. Keckler SJ, St Peter SD, Valusek PA, Tsao K, Snyder CL, Holcomb GW 3rd, Ostlie DJ. VACTERL anomalies in patients with esophageal atresia: an updated delineation of the spectrum and review of the literature. *Pediatr Surg Int* 2007; 23: 309-13.
4. Usui N, Kamata S, Ishikawa S, Sawai T, Okuyama H, Imura K, Okada A. Anomalies of the tracheobronchial tree in patients with esophageal atresia. *J Pediatr Surg* 1996; 31: 258-62.
5. Stark Z, Patel N, Clarnette T, Moody A. Triad of tracheoesophageal fistula-esophageal atresia, pulmonary hypoplasia, and duodenal atresia. *J Pediatr Surg* 2007; 42: 1146-8.
6. Fayoux P, Morisse M, Sfeir R, Michaud L, Daniel S. Laryngotracheal anomalies associated with esophageal atresia: importance of early diagnosis. *Eur Arch Otorhinolaryngol* 2018; 275: 477-481.
7. Clements BS. In Landau LI, Taussig LM, editors. Congenital malformations of the lung and airways. *Pediatric Respiratory Medicine St. Louis (MO)*: Mosby; 1999. Pp1106-1136.
8. Sugandhi N, Sharma P, Agarwala S, Kabra SK, Gupta AK, Gupta DK. Esophageal lung: presentation, management, and review of literature. *J Pediatr Surg* 2011; 46: 1634-7.
9. Garge S, Rao KLN, Bawa M. The role of preoperative CT scan in patients with tracheoesophageal fistula: a review. *J Pediatr Surg* 2013; 48: 1966-71.
10. Mahalik SK, Sodhi KS, Narasimhan KL, Rao KL. Role of preoperative 3D CT reconstruction for evaluation of patients with esophageal atresia and tracheoesophageal fistula. *Pediatr Surg Int* 2012; 28: 961-6.
11. Briganti V, Oriolo L, Buffa V, Garofalo S, Cavallaro S, Calisti A. Tracheomalacia in oesophageal atresia: morphological considerations by endoscopic and CT study. *Eur J Cardiothorac Surg* 2005; 28: 11-5.
12. Lee EY, Siegel MJ, Hildebolt CF, Gutierrez FR, Bhalla S, Fallah JH. MDCT evaluation of

- thoracic aortic anomalies in pediatric patients and young adults: comparison of axial, multiplanar, and 3D images. *AJR Am J Roentgenol* 2004; 182: 777-84.
13. Thakkar H, Upadhyaya M, Yardley IE. Bronchoscopy as a screening tool for symptomatic tracheomalacia in oesophageal atresia. *J Pediatr Surg* 2018; 53: 227-229.
  14. Berrocal T, Madrid C, Novo S, Gutiérrez J, Arjonilla A, Gómez-León N. Congenital anomalies of the tracheobronchial tree, lung, and mediastinum: embryology, radiology, and pathology. *Radiographics* 2004; 24: e17.
  15. Muensterer O, Abellar R, Otterburn D, Mathew R. Pulmonary Agenesis and Associated Pulmonary Hypertension: A Case Report and Review on Variability, Therapy, and Outcome. *European J Pediatr Surg Rep* 2015; 3: 33-9.
  16. Stoll C, Alembik Y, Dott B, Roth MP. Associated anomalies in cases with esophageal atresia. *Am J Med Genet A* 2017; 173: 2139-2157.
  17. Sistonen S, Malmberg P, Malmström K, Haahtela T, Sarna S, Rintala RJ, Pakarinen MP. Repaired esophageal atresia: Respiratory morbidity and pulmonary function in adults in a population-based long-term follow-up study. *Eur Respir J* 2010; 36: 1106-12.
  18. De Felice C, Di Maggio G, Messina M, Toti P, Bagnoli F, Bracci R, Tota G. Congenital cystic adenomatoid malformation of the lung associated with esophageal atresia and tracheoesophageal fistula. *Pediatr Surg Int* 1999; 15: 260-3.
  19. Lima M, Dòmini M, Aquino A, Ruggeri G, Libri M, Tursini S, et al. The role of emergency thoracoscopy in the management of congenital cystic adenomatoid malformation of the lung associated with oesophageal atresia. *Eur J Pediatr Surg* 2005; 15: 279-82.
  20. He QM, Xiao SJ, Zhu XC, Xiao WQ, Wang Z, Zhong W, Xia HM. Communicating bronchopulmonary foregut malformation type IA: radiologic anatomy and clinical dilemmas. *Surg Radiol Anat* 2015; 37: 1251-6.
  21. Srikanth MS, Ford EG, Stanley P, Mahour GH. Communicating bronchopulmonary foregut malformations: classification and embryogenesis. *J Pediatr Surg* 1992; 27: 732-6.
  22. Mentessidou A, Avgerinos I, Avgerinos N, Skandalakis PN, Mirilas P. Right or left thoracotomy for esophageal atresia and right aortic arch? Systematic review and

- surgicoanatomic justification. *J Pediatr Surg* 2018; 53: 2128-2135.
23. Canty TG Jr, Boyle EM Jr, Linden B, Healey PJ, Tapper D, Hall DG, et al. Aortic arch anomalies associated with long gap esophageal atresia and tracheoesophageal fistula. *J Pediatr Surg* 1997; 32: 1587-91.
24. Berthet S, Tenisch E, Miron MC, Alami N, Timmons J, Aspirot A, Faure C. Vascular Anomalies Associated with Esophageal Atresia and Tracheoesophageal Fistula. *J Pediatr* 2015; 166: 1140-1144.e2.
25. Ergun E, Şimşek B, Koşar PN, Yılmaz BK, Turgut AT. Anatomical variations in branching pattern of arcus aorta: 64-slice CTA appearance. *Surg Radiol Anat* 2013; 35: 503-9.
26. Jakanani GC, Adair W. Frequency of variations in aortic arch anatomy depicted on multidetector CT. *Clin Radiol* 2010; 65: 481-7.
27. Sheikh AS, Mazhar S. Persistent Left Superior Vena Cava with Absent Right Superior Vena Cava: Review of the Literature and Clinical Implications. *Echocardiography* 2014; 31: 674-9.
28. de Jong EM, Felix JF, Deurloo JA, van Dooren MF, Aronson DC, Torfs CP, et al. Non-VACTERL-type anomalies are frequent in patients with esophageal atresia/tracheoesophageal fistula and full or partial VACTERL association. *Birth Defects Res A Clin Mol Teratol* 2008; 82: 92-7.
29. Ngercham M, Lee EY, Zurakowski D, Tracy DA, Jennings R. Tracheobronchomalacia in pediatric patients with esophageal atresia: comparison of diagnostic laryngoscopy/bronchoscopy and dynamic airway multidetector computed tomography. *J Pediatr Surg* 2015; 50: 402-7.
30. Wallis C, Alexopoulou E, Antoin-Pacheco JL, Bhatt JM, Bush A, Chang AB, et al. ERS Statement on Tracheomalacia and Bronchomalacia in Children. *Eur Respir J* 2019; pii: 1900382.
31. Higano NS, Bates AJ, Tkach JA, Fleck RJ, Lim FY, Woods JC, Kingma PS. Pre- and post-operative visualization of neonatal esophageal atresia/tracheoesophageal fistula via magnetic resonance imaging. *J Pediatr Surg Case Rep* 2018; 29: 5-8.

**Table 1: Sample characteristics of the 48 patients**

Characteristics	n (%)
<b>Demographic and neonatal characteristics</b>	
- Male	27/48 (56)
- Preterm birth	16/48 (33)
- Single umbilical artery	6/48 (13)
- Age (years) at CT scan, median (range)	4 years, 5 months (1 day-16 years, 2 months)
<b>Ladd classification of oesophageal atresia *</b>	
- Type I	4/48 (8)
- Type II	2/48 (4)
- Type III	39/48 (81)
- Type IV	3/48 (6)
<b>Associated syndrome</b>	
- VACTERL association	13/48 (27)
- 22q11.2 deletion	1/24 (4)
- Chromosome 15q duplication	1/24 (4)
<b>Associated malformations</b>	
- Congenital heart disease	15/47 (32)
- Malformation of the urogenital tract	14/48 (29)
- Malformation of the skeleton	14/47 (30)
- Malformation of the gastrointestinal tract	6/47 (13)
- Laryngeal supraglottic malformation	4/47 (8)
- Other malformation	20/47 (43)
- Malformations of $\geq 2$ organ systems	23/47 (49)
<b>Tracheomalacia</b>	22/30 (73)

Values reported as frequency (percentage) or median (range). There was one missing value for five of the six associated malformations because the child was not born in our centre and was followed up in the later years.

CT, computed tomography.

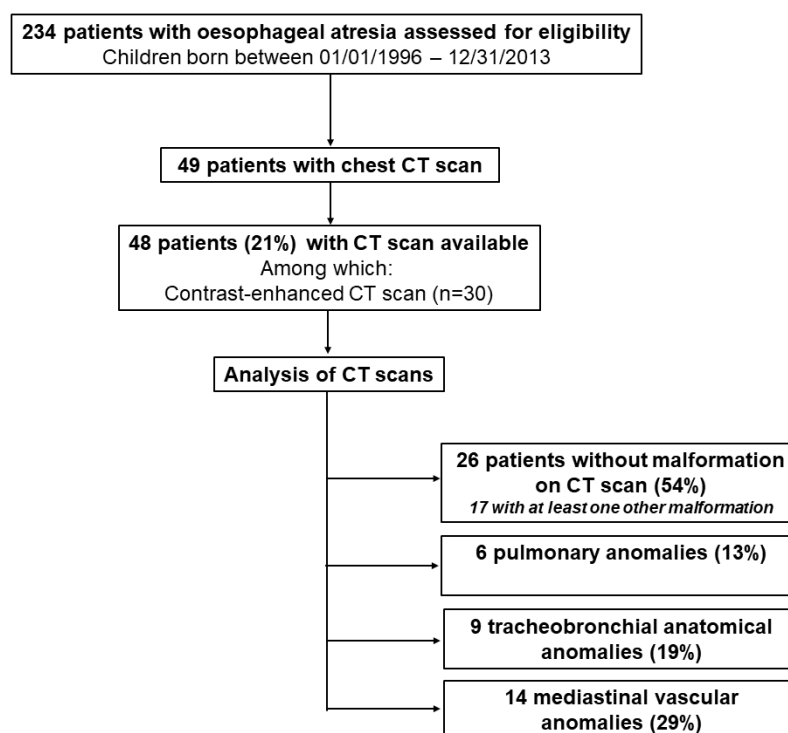
\*As defined by Ladd et al (1)

**Table 2: Associated malformations in six patients with congenital pulmonary malformations**

<b>Patient</b>	<b>Type of oesophageal atresia *</b>	<b>Pulmonary malformation</b>	<b>Other anomalies</b>
<b>Patient a</b>	III	Right pulmonary aplasia	Ventricular septal defect – arteria lusoria
<b>Patient b</b>	III	Agenesis of the right upper and middle lobes	<b>VACTERL Association</b> Laryngeal diastema Coarctation of the aorta - atrial septal defect Partial right anomalous pulmonary venous return Vesicoureteral reflux Ear malformation
<b>Patient c</b>	III	Agenesis of the right upper and middle lobes	Arteria lusoria – persistent left superior vena cava Intestinal malrotation
<b>Patient d</b>	III	Agenesis of the middle lobe	<b>VACTERL Association</b> Tracheal stenosis Arteria lusoria – persistent left superior vena cava Hemivertebrae Rib anomaly Right radial polydactyly
<b>Patient e</b>	III	Agenesis of the middle lobe	Duodenal atresia Multicystic kidney
<b>Patient f</b>	III	Congenital cystic adenomatoid malformation	<b>VACTERL Association</b> Coarctation of the aorta – persistent left superior vena cava Congenital block vertebrae Imperforate anus Multicystic kidney

\* As defined by Ladd et al (1)

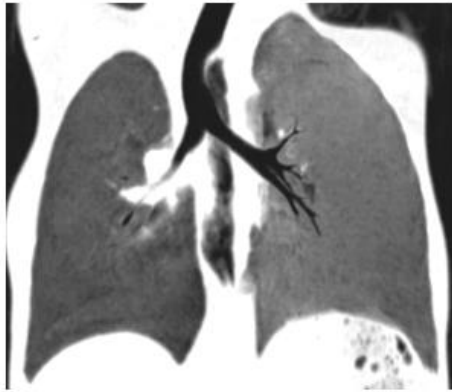**Figure 1: Sample flow chart**



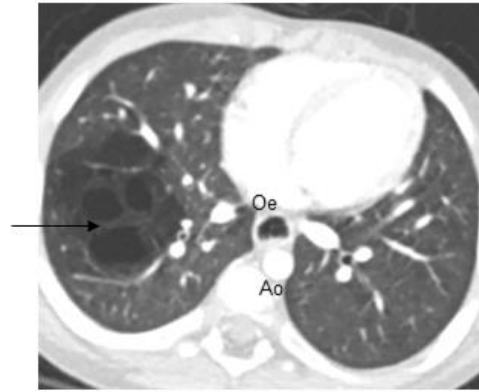
CT, computed tomography

**Figure 2: Examples of malformations seen on contrast-enhanced chest CT**

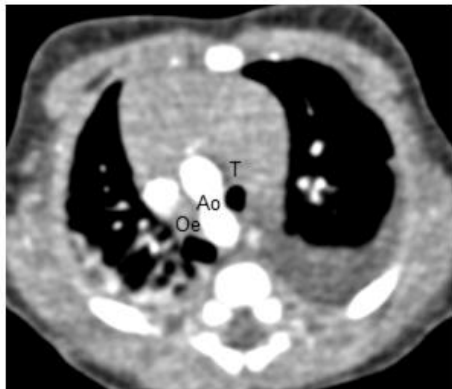CT, computed tomography.



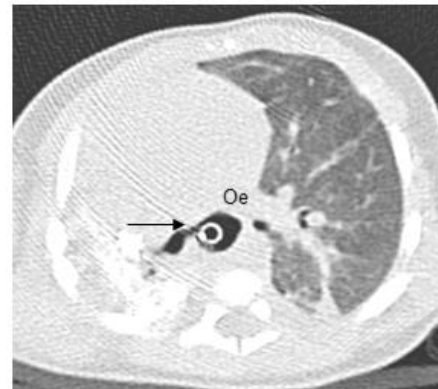
**a) Oesophageal atresia child with middle and upper right lobes agenesis (coronal minimum intensity projection reconstruction)**  
*Note the absence of right upper and middle lobes and bronchi and the small size and hyperlucency of the right lung*



**b) Oesophageal atresia child with a congenital cystic adenomatoid malformation (arrow) affecting right middle and lower lobes**



**c) Oesophageal atresia child with right-sided aortic arch**  
*Note that aorta stands between oesophagus and trachea after oesophageal atresia repair*

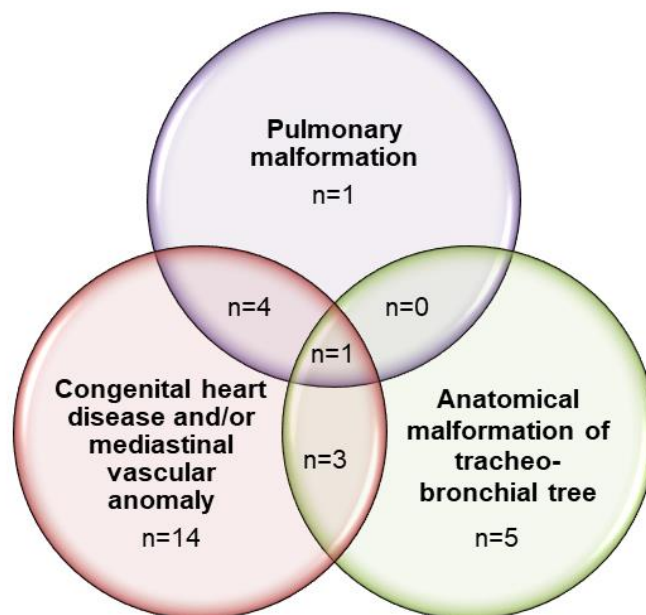


**d) Oesophageal atresia child with a communicating bronchopulmonary foregut malformation**  
*The arrow points out at the right main stem bronchus originating from the oesophagus. Note the presence of a feeding tube inside the oesophagus*  
*Ao: aorta; Oe: oesophagus; T: trachea*

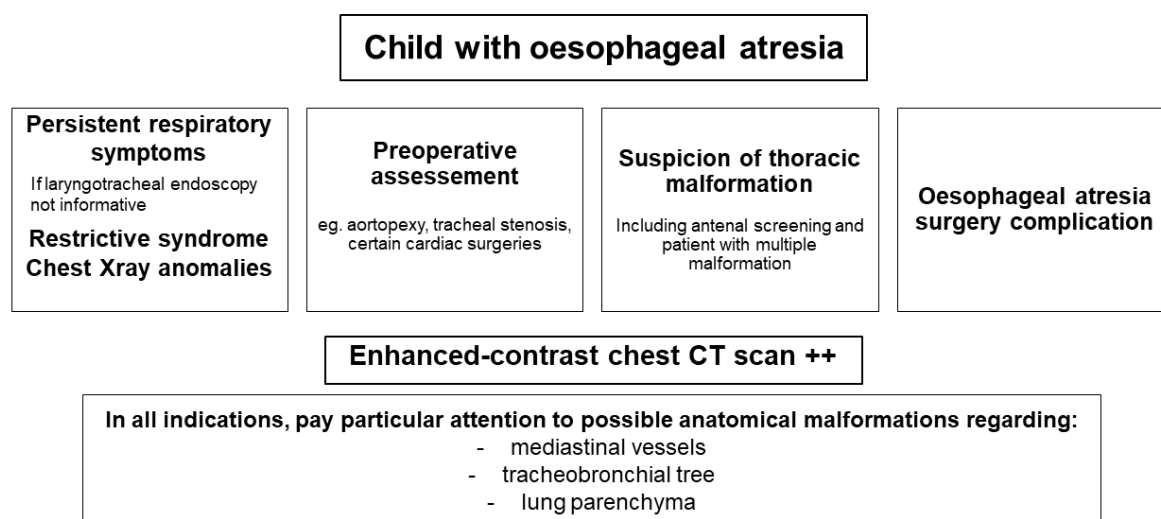
*Ao: aorta; Oe: oesophagus; T: trachea*

**Figure 3: Associations of pulmonary, vascular, and trachea-bronchial malformations**





**Figure 4: Proposed decision tree on the role of chest CT scans in patients with repaired oesophageal atresia**



*Exploration of these anomalies can require other exams, such as laryngotracheal endoscopy and echocardiography*

CT, computed tomography.

